

¡DISPONIBLE YA!  
Solicítelo online en  
[www.kuglerpublications.com](http://www.kuglerpublications.com)



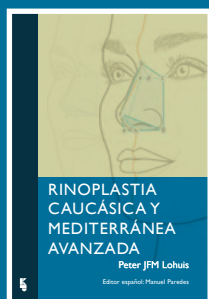
# RINOPLASTIA CAUCÁSICA Y MEDITERRÁNEA AVANZADA

Peter JFM Lohuis

Editor español: Manuel Paredes



OFERTA ESPECIAL • 10% DE DESCUENTO



## RINOPLASTIA CAUCÁSICA Y MEDITERRÁNEA AVANZADA

Peter JFM Lohuis, MD PhD

Editor español: Manuel Paredes

ISBN: 978-90-6299-244-7.

2015. xx y 414 páginas. Formato A4. Tapa dura.

Numerosas fotografías e ilustraciones a todo color.

Precio de lista: € 150 / US \$ 180\*

**PRECIO CON DESCUENTO: € 135 / US \$ 162\***

El libro sigue el adagio chino según el cual “una imagen vale más que mil palabras”. En el último decenio, el autor desarrolló el hábito de llevar su cámara constantemente al quirófano, lo cual formó la base de muchas de las fotografías intraoperatorias de rinoplastia de estructura abierta a todo color.

El texto se encuentra dividido en pequeños capítulos escritos en forma de perlas y unidos de manera hilvanada. Las numerosas ilustraciones esquemáticas y comprensibles ayudan a elucidar el texto.

La visión desplegada en este libro servirá, con suerte, como ejemplo para que el joven cirujano desarrolle su propia estrategia para obtener buenos resultados de forma consistente en el tratamiento de casos de rinoplastia caucásica y mediterránea.

### Tabla de contenido

- |          |  |           |                                      |
|----------|--|-----------|--------------------------------------|
| <b>1</b> | LA CURVA DE APRENDIZAJE DE RINOPLASTIA   | <b>9</b>  | LAS COMPLICACIONES EN LA RINOPLASTIA |
| <b>2</b> | CONSIDERACIONES PREOPERATORIAS           | <b>10</b> | EL CUESTIONARIO UTRECHT PARA LA      |
| <b>3</b> | ANÁLISIS DE LA RINOPLASTIA               |           | EVALUACIÓN DE RESULTADOS EN          |
| <b>4</b> | ASPECTOS FUNCIONALES DE LA RINOPLASTIA   | <b>11</b> | RINOPLASTIA                          |
| <b>5</b> | FUNDAMENTOS DE LA CIRUGÍA DE LA PUNTA    | <b>12</b> | CONSIDERACIONES POSTOPERATORIAS      |
|          | NASAL                                    | <b>13</b> | PROBLEMAS ESPECIALES                 |
| <b>6</b> | SOLUCIONES AVANZADAS PARA LA PUNTA NASAL | <b>14</b> | CASOS                                |
| <b>7</b> | EL DORSO NASAL Y LA PIRÁMIDE NASAL       | <b>15</b> | RECONSTRUCCIÓN NASAL                 |
| <b>8</b> | LOS MATERIALES DE INJERTO EN LA          | <b>16</b> | BIBLIOGRAFÍA                         |
|          | RINOPLASTIA                              |           |                                      |

Por favor utilice el código de descuento **RHINO14** para obtener un descuento del 10% al realizar su pedido en [www.kuglerpublications.com](http://www.kuglerpublications.com).

\*No incluye 6% de IVA (aplicable solo para clientes en la Unión Europea) y costos de envío.

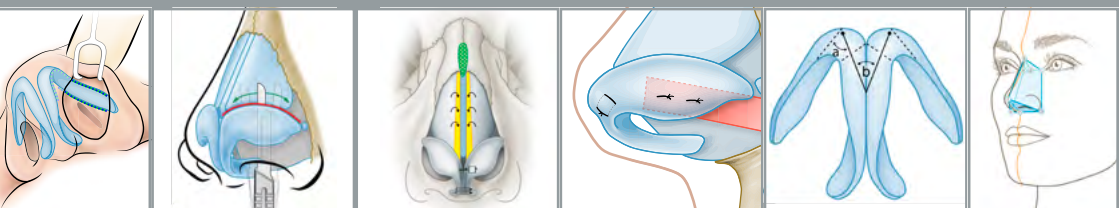


KUGLER PUBLICATIONS


P.O. Box 20538 | 1001 NM Amsterdam | The Netherlands

T: + 31 20 68 45 700 | E: [info@kuglerpublications.com](mailto:info@kuglerpublications.com)

[www.kuglerpublications.com](http://www.kuglerpublications.com)



## VALORACIÓN



“No conozco ningún otro libro que considere y describa de forma tan excepcionalmente detallada temas como la curva de aprendizaje de rinoplastia, el cuestionario Utrecht, y los problemas especiales. Cuando revisé la bibliografía, pude constatar que el autor ha realizado una investigación bibliográfica extensa y ha recopilado una cantidad tremenda de información valiosa en el libro. Ha sido presentada de forma clara, concisa y atractiva, no solo en fotografías, diagramas y gráficos, sino también en su claridad e integridad intelectual. Es uno de los manuales de rinoplastia más valiosos que he tenido el privilegio de leer.”

Peter A. Adamson, MD, FRCSC, FACS

Ex presidente de la Academia Americana de Cirugía  
Plástica Facial y Reconstructiva

“Peter Lohuis es una de las estrellas ascendentes de la plástica facial europea y mundial, y es por ello razonable que cualquier tomo que publique sea un trabajo a tener en consideración, con mucho cuidado en los detalles. Este libro proporciona exactamente eso, una visión que invita a reflexionar sobre la rinoplastia.”

Simon Watts FRCS (ORL HNS) Brighton UK

“Además de su claridad y concisión, el libro tiene la ventaja de haber sido escrito por un único cirujano con amplia experiencia en rinoplastia funcional y estética. Esto proporciona continuidad en la terminología y los conceptos. Es por ello que este manual probará ser una referencia valiosa y una guía quirúrgica informativa para cualquier cirujano que realice rinoplastia.”

Profesor Shan R. Baker

Ex presidente del Consejo Americano de Cirugía Plástica Facial y Reconstructiva

## 2.12 Local and general anesthesia

A. The key to good anesthesia is comfort, safety and structured communication between the surgeon and the anesthesiologist.

B. All my rhinoplasty patients are operated under general anesthesia resulting in complete amnesia, analgesia, and sedation. Complementary topical and local infiltration anesthetics deliver analgesia and vasoconstriction and result in a more or less 'dry' operating field.

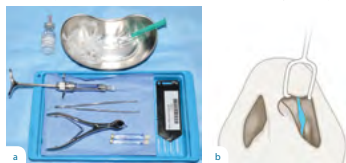

Fig. 4. The tray used for local anesthesia with Xylocaine 1% with 1:100,000 epinephrine and a typically applied cocaine solution (a). Exposure as it is obtained during infiltration using a 10-mm skin hook or a speculum (b).

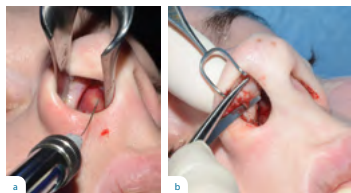


Fig. 5. A 27-gauge needle on a dentist syringe is very helpful for the deposition of local anesthetic agent in the submucoperichondrial plane of the septum and in the incision lines (a). Vibrissae are cut preoperatively with a dull pointed scissor for maximum visualization during surgery (b).

and extensive septal tunnelling on both sides, the connection between the medial crura and the caudal septum becomes compromised in a similar fashion as with transfixion.

D. The incisions frequently used in rhinoplasty are listed on the next page, together with their indications.

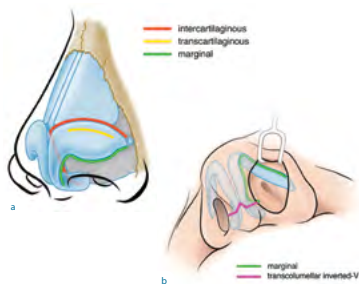


Fig. 7. Several incisions to gain exposure of dorsum, septum and alar cartilages. Endonasal approach (a) and external approach (b).

### INDICATION

Caudal septum incision (hemitransfixion)  
Transfixion incision  
Intercartilaginous incision  
Vestibular incision  
Infracartilaginous incision  
Transcolumellar inverted-V incision  
V-incision columellar base  
Transcartilaginous incision

### INDICATION

Septoplasty, endonasal approach  
Deprojection, endonasal approach  
Endonasal approach  
Osteotomies  
Delivery technique, external approach  
External approach  
Cleft lip deformity  
Combines cephalic rim resection and intercartilaginous approach

## 3.8 Rhinoplasty: a play of shadow and light

A. Awareness of the aesthetic subunit principle can be a powerful accelerator of the rhinoplasty learning curve (Fig. 12). A detailed analysis of nasal subunits based on intrinsic contour configurations and the psychology of perception has been provided in detail by Burget and Menick.

The nose has multiple, well-defined, aesthetic units with distinct contour, colour, consistency, sebaceous content, texture and function. In nasal reconstruction, suture lines should rest in the lines between the subunits to avoid being conspicuous. Ideally the entire subunit is resurfaced to minimize color and texture changes.

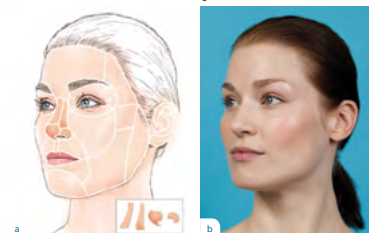


Fig. 12. Aesthetic subunit principal displayed.

B. The surface of the nose is crossed by shallow ridges and valleys that separate it into slightly convex or slightly surfaces: the tip, the columella, the dorsum, paired sidewalls, alar lobules, and soft triangles. Light is reflected on these different surfaces with a different intensity creating patterns of shadow and light which are transported to the retina and transmitted as an electrical impulse to the brain (Fig. 13).

C. How we consciously 'see' the nose also depends on how complex mental processes influence our conscious mental perception. We 'see' color, texture, and contour changes. The absence of a feature unit can 'surprise' the eye and causes it to stop in its normal unconscious scanning pattern to focus on the 'unexpected'.

## 5.3 The scar in the open approach

A. Disadvantages of the external approach include the transcolumellar scar. Several investigations have proven the transcolumellar scar to be more of an issue for the surgeon than for the patient. When care is taken to close the incision without subcutaneous tension and with careful eversion and adaptation of skin edges, the transcolumellar scar is hardly visible and of minor significance in the majority of patients (Fig. 3A). Sometimes up to seven or eight 6-0 nylon sutures can be required to divide the skin over the line of incision.

B. The broken transcolumellar incision is connected to both infracartilaginous incisions. The transcolumellar incision follows the relaxed skin tension line, but is broken up to enhance camouflage and prevent scar retraction. The position of the transcolumellar scar is critical to the end result and should be placed in the middle between the most cephalic part of the nostril and the beginning of the diverging footplates of the medial crura (Fig. 3B). Placing the scar to close to the medial crura might lead to scar retraction and step-off deformity.

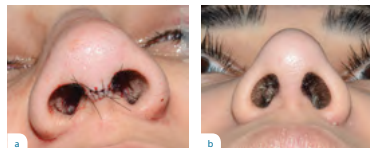


Fig. 3A. Careful eversion and adaptation of skin edges using sometimes up to seven or nine 6-0 nylon sutures (a) will leave the transcolumellar scar hardly visible and of minor significance in the majority of patients (b).

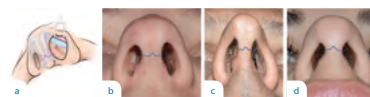

Fig. 3B. The position of the transcolumellar scar is critical for the end result and should be placed in the middle between the most cephalic point of the nostrils and the point where the medial crural footplates start diverging.

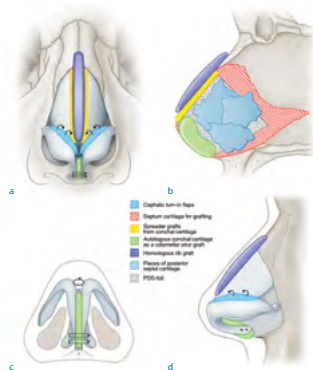
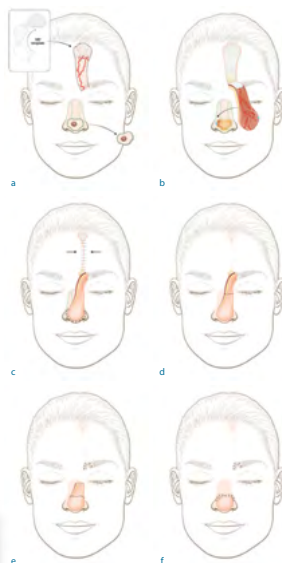


Fig. 3. Surgical steps.

#### Surgical steps

- External approach
- Transalar septal tunneling
- Harvesting of conchal cartilage
- Harvesting the remaining pieces of posterior septal cartilage
- Septal reconstruction using PDS-foil as a template
- Spreader grafts from conchal cartilage are sutured to the reconstructed septum to widen and strengthen the nasal dorsum
- Autologous conchal cartilage at the base of the template serves as a columellar strut graft
- Cephalic turn-in flap to strengthen the lateral crus
- Tongue-in-groove technique to stretch the medial crura and correct the columellar retraction
- Interdomal suture

#### 14. NASAL RECONSTRUCTION



#### Intraoperative photos

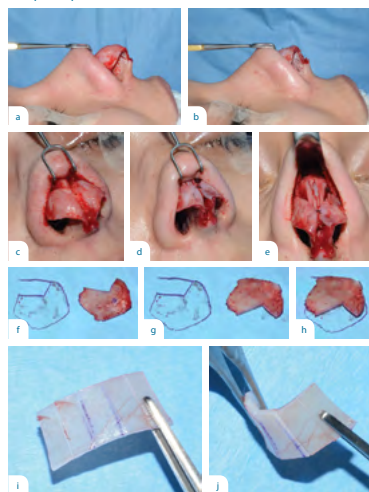


Fig. 4. The ptotic tip (a, c) is refined and upwardly rotated with tips sutures and tongue-in-groove technique (b, d). The nasal dorsum (e) is corrected by subtotal extracorporeal septoplasty transformed into a left-sided spreader graft (f, g, h). A small piece of cartilage is longitudinally incised and used as a radii graft (i, j).

#### Case study 10

Major deformity  
Crooked nose.

Minor deformity  
Overprojected tip, dorsal hump, ptotic tip.

#### History

This 27-year-old man wanted to have something done about his large, crooked nose. Also, his breathing was bilaterally impaired.

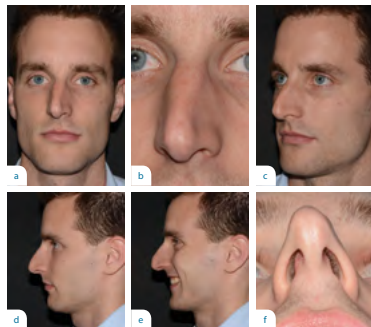



Fig. 1. Preoperative photos of the patient.

#### Analysis of preoperative photos

The strong, squared features in the face of this male patient are completely distracted by a crooked, overprojected nose. In the basal view, note the slitlike nares of this 'tension nose' and how much anteriorly the medial crural footplates are positioned as a result of the excessive outgrowth of the nasal spine.



## Formulario de Pedido

Por favor envíe su orden a la dirección postal o la dirección de correo listada más abajo, o solicite su ejemplar en **www.kuglerpublications.com** utilizando el código de descuento **RHINO14**.

Me gustaría solicitar: **Rinoplastia Caucásica y Mediterránea Avanzada** de **Peter JFM Lohuis** por el precio especial de € 135 / US \$ 162.

Número de ejemplares: ..... Total: € .....

Fecha: ..... Firma: .....

Número de cuenta: .....

Fecha de validez: ..... No. de IVA: .....

Código de seguridad de la tarjeta de crédito: .....

Nombre : .....

E-mail: .....

Dirección de facturación

Dirección de envío (de ser distinta)

.....	.....
.....	.....
.....	.....
.....	.....
.....	.....
.....	.....

Los costos de envío dependen del destino, la modalidad de envío y el peso.

Aproximación de costos de envío (0-5KG):

- Europe: € 6-20
- Resto del mundo: €8-30

Por favor ingrese a nuestra página web para determinar los costos y condiciones de envío.



KUGLER PUBLICATIONS

P.O. Box 20538 | 1001 NM Amsterdam | The Netherlands

T: + 31 20 68 45 700 | E: [info@kuglerpublications.com](mailto:info@kuglerpublications.com)

[www.kuglerpublications.com](http://www.kuglerpublications.com)